Colorectal endoscopic submucosal dissection: a review on patient selection and indications

M. Bronswijk[1,2,3], G. Rasschaert[4], Y. Hayashi[5], H. Yamamoto[5]

(1) Department of Gastroenterology and Hepatology, Imelda General Hospital, Bonheiden, Belgium; (2) Department of Gastroenterology and Hepatology, University Hospitals Leuven, KU Leuven, Belgium; (3) Imelda Clinical GI Research Center, Bonheiden, Belgium; (4) Department of Gastroenterology and Hepatology, Universitair Ziekenhuis Brussel, Brussels, Belgium.; (5) Division of Gastroenterology, Department of Medicine, Jichi Medical University, Tochigi, Japan.

Abstract

Background: **The development of 'third-space'-endoscopy has paved the way towards en-bloc resection of early gastrointestinal neoplasia. Endoscopic submucosal dissection (ESD) has improved the endoscopic management of colorectal lesions by facilitating R0-resection, improving histological assessment and preventing recurrence.**

Methods: **The purpose of this review is to provide an evidence-based overview of indications for which ESD should be considered within colorectal endoscopy.**

Results: **The development of ESD has partially bridged the gap between endoscopy and surgery, but depends heavily on adequate pre-resection visual evaluation, ruling out potential deep submucosal invasion. ESD should be considered for large colorectal polyps (≥20mm) and/or lesions diagnosed as harbouring high-grade dysplasia, in-situ carcinoma or superficial submucosal invasion. Not only has it found its way into our guidelines for the treatment of neuroendocrine neoplasms, ESD also seems a promising alternative for the controlled resection of large pedunculated lesions. ESD can also be applied in more challenging situations, such as in pre-treated lesions, post-surgical context and in patients with IBD, although this requires a high level of skill and expertise.**

Conclusions: **In this review we have described the different indications for ESD and attempted to define its place within our current endoscopic armamentarium. For both non-expert and expert endoscopists, knowledge about ESD indications, patient selection and therapeutic alternatives, remains crucial in the care for patients with colorectal neoplasia.** (Acta gastroenterol. belg., **2023,** 86, **36-46**).

Keywords: ESD, EMR, colorectal cancer, pocket-creation method, neuroendocrine tumors, laterally spreading tumors.

Abbreviations: AR: anastomotic recurrence; eFTR: endoscopic full-thickness resection; EMR: endoscopic mucosal resection; ESD: endoscopic submucosal dissection; EUS: endoscopic ultrasound; JNET: Japan Narrow-Band-Imaging (NBI) Expert Team; LST: laterally spreading tumor; LST-G-H: laterally spreading tumor-granular-homogenous; LST-G-NM: laterally spreading tumor-granular-homogenous; LST-NG-FE: laterally spreading tumor-nongranular-flat elevated; LST-NG-PD: laterally spreading tumor-nongranular-pseudodepressed; MRI: magnetic resonance imaging; NEN: neuroendocrine neoplasms; PCM: pocket-creation method; POEM: peroral endoscopic myotomy; STER: submucosal tunnelling endoscopic resection; TEM: transanal endoscopic microsurgery; UC: ulcerative colitis; UCAN: ulcerative colitis-associated neoplasia; WLI: White light imaging

Introduction

The submucosa of the gastrointestinal tract consists of a matrix of proteins such as laminin, fibronectin and collagen. In the early stages of advanced endoscopy, it was discovered that this layer between the muscularis mucosae and muscularis proper could be expanded using endoscopic injection of lifting agents, leading to mucosal elevation. Opening up the submucosa by needle injection of colloids and/or saline, creates a virtual space that has paved the way towards the development of submucosal endoscopy, also termed third-space endoscopy (1-3). Endoscopic submucosal dissection (ESD) was one of the first third-space techniques (1-5), soon to be followed by peroral endoscopic myotomy (POEM) (6,7) and submucosal tunnelling endoscopic resection (STER) (8). Based on the concept that this virtual space can be safely accessed without compromising the integrity of the mucosa and muscularis proper, en-bloc resection by ESD has become a fixed value within the endoscopic armamentarium, aimed at treating early gastrointestinal neoplasia.

Initial experiences in ESD mainly consisted of Japanese series in the context of early gastric cancer and were followed by oesophageal ESD for squamous neoplasia and adenocarcinoma, as well as colorectal lesions in the early 2000's (4,9-12). Since then, various advances have been made optimizing the technique itself. These have included: improvements in lifting agents, electrosurgical devices and settings, distal attachments, dedicated scopes and accessories, as well as developments regarding dissection techniques, such as the pocket-creation method (PCM) and traction-assisted dissection (4,13-21). Superior outcomes of this technique have led to its widespread distribution beyond the far East, with increasing amounts of Western centers adopting colorectal ESD. Perhaps due to the vast amount of innovations in this specific area of endoscopy, it can be challenging to keep track of which colorectal lesions can currently be considered for ESD.

The purpose of this review is to provide an evidence-based overview of indications for which ESD should be considered within colorectal endoscopy.

Correspondence to: Michiel Bronswijk, MD, Imelda Hospital Bonheiden, Imeldalaan 9, 2820 Bonheiden, Belgium.
Email: mjh.bronswijk@gmail.com

Submission date: 04/07/2022
Acceptance date: 07/11/2022

Preprocedural diagnostics

Similar to other fields within medicine, patient selection remains of the utmost importance. Before embarking on endoscopic resection in general, the target lesion should therefore be thoroughly evaluated and efforts should be made to rule out deep submucosal invasion.

Optical diagnosis

Since the last two decades, several tools and classifications have been developed to optimize visual diagnosis.

Kudo's classification, published in 1996, relies on magnification endoscopy and facilitates accurate immediate assessment of colorectal neoplastic lesions (22,23). By subdividing polyps in non-neoplastic lesions (I & II), adenomatous lesions with low grade dysplasia (IIIS & IIIL), tubulovillous adenoma (IV) and more advanced lesions into V_I (irregularly arranged pits) and V_N (non-structured pits), the Kudo classification has become a household name for lesion characterization using pit pattern recognition far beyond the Japanese borders (Figure 1). Where IIIS, IIIL and IV lesions can be treated with endoscopic resection, V_N lesions should be considered for surgery. For colorectal neoplasms exhibiting a V_I pattern, care should be taken to distinguish invasive from non-invasive lesions. Another visual diagnostic tool that can be used in such circumstances, is the widely accepted Japan Narrow-Band-Imaging (NBI) Expert Team (JNET) classification (24,25). Using NBI and magnification, this classification depends on both vessel and surface pattern recognition, subdividing lesions in Type 1, Type 2A & 2B and Type 3. Ranging from invisible vessels (Type 1), regular or irregular vessels (Type 2A & 2B) to loose vessels and amorphous areas (Type 3), these surface and vessel patterns aid in accurately classifying these lesions from hyperplastic lesions, low & high grade dysplasia, up towards deep invasive cancer (26). For shallow submucosal invasive carcinomas (Type 2B), sensitivity and overall diagnostic accuracy were lower when compared to Type 1, Type 2A and Type 3 lesions, reflecting the ongoing clinical challenge in identifying shallow invasive cancer amendable for endoscopic resection.

Not only pit or vessel patterns can be used in staging colorectal neoplasia, also lesion morphology and size should be recorded and described (27). Here, the Paris classification has been fixed value for years (Figure 2) (28). For larger flat and/or sessile lesions ≥ 10mm, termed laterally spreading tumors (LSTs) (29), a different subclassification should be considered.

These LSTs, by definition lesions that are typically wider than high, are currently subdivided into either granular or non-granular subtypes, depending on surface pattern and overall morphology. Granular LSTs may exhibit a homogenous (LST-G-H) or nodular mixed (LST-G-M) morphology, whereas non-granular LSTs

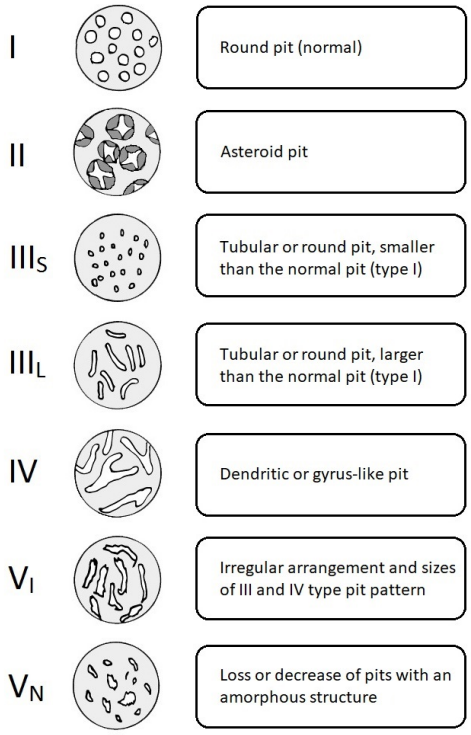

Figure 1. — Kudo classification.

have been subdivided in flat elevated (LST-NG-FE) or pseudodepressed (LST-NG-PD) lesions (Figure 2) (30). These subtypes are known to follow distinct molecular pathways and correlate well with the risk of submucosal invasion. A large meta-analysis in 2018 showed that this risk was lowest in LST-G-H (0.5%) and LST-NG-FE lesions (4.9%), whereas the risk of submucosal invasion reached 31.6% and 10.5% in the LST-NG-PD and LST-G-M groups respectively (31).

Optical diagnosis should be regarded as a two-step procedure with: 1) thorough macroscopic evaluation using white light imaging (WLI) following cleaning and optimal insufflation, and 2) a more in-depth analysis of suspicious areas with WLI, virtual chromoendoscopy and other image enhancement techniques. Suspicious areas in these lesions typically have a more reddish aspect on WLI, and more green aspect using NBI. Although the combination of both steps should ensure an optimal prediction of the risk of deep submucosal invasion, the sensitivity for optical detection of deep submucosal invasive cancer varies from 67.1% to 83.3%, even in expert hands (32,33). An overall submucosal invasive cancer miss rate of 3% has been reported, with predominantly size ≥40mm, rectosigmoid location and nodular morphology as independent risk factors for missed submucosal invasive cancer (34). Despite these limitations, an organ-sparing approach with first-line ESD ought to be discussed in cases with inconsistent results during optical evaluation, given the limited oncological impact should secondary surgical treatment prove necessary over time.

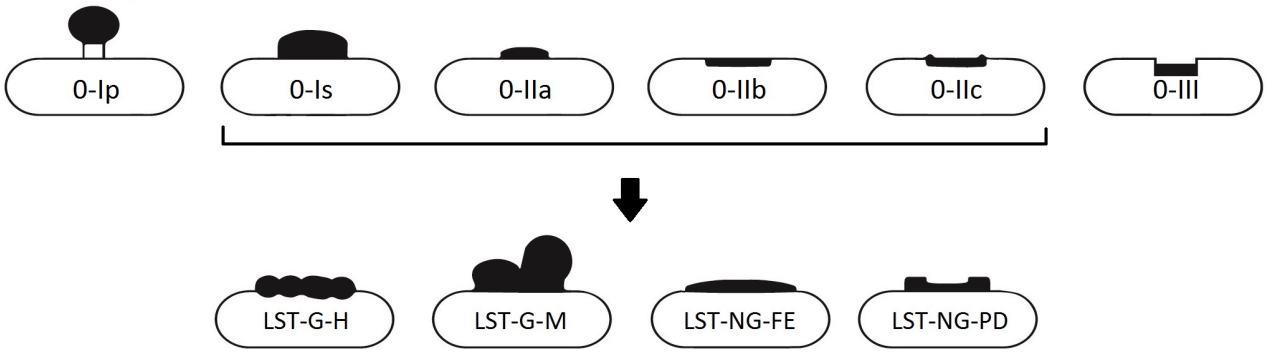

Figure 2. — Paris classification and lateral spreading tumor (LST) subtypes.

Role for EUS and MRI

Two studies have compared magnification chromoendoscopy with endoscopic ultrasound (EUS) for the detection of >1000µm submucosal invasion (sm2) with mixed results. In 2014, Shimura et al. showed equal accuracy of EUS and magnification chromoendoscopy in 70 cases of early colorectal cancer (35), whereas an early study by Matsumoto et al. showed higher negative predictive value for EUS (36). Routine performance of EUS prior to resection is not recommended (37), although pre-resection staging with EUS can be considered in distal lesions with very large sessile components, which are challenging to evaluate with optical diagnosis alone (38). As for magnetic resonance imaging (MRI), we know that this imaging modality is known to overstage early colorectal lesions in over half of patients and should therefore not be used for transmural staging. For these reasons pre-resection EUS and MRI are not recommended, provided that there are no optical features suggestive of deep submucosal invasion.

Role for pre-resection sampling

In general, biopsies are not recommended in the work-up of potentially resectable disease, provided the lesion has been adequately evaluated by an endoscopist trained in visual diagnosis, and no features suggestive of deep submucosal invasion have been identified (39). Previous resection attempts and endoscopic tattooing, but also pre-resection sampling have furthermore been associated with submucosal fibrosis, potentially compromising submucosal lifting and subsequent resection (39,40). Furthermore pre-resection sampling can lead to false reassurance, and sampling error should therefore be taken into account, depending on the biopsy site. On the other hand, a 2012 Japanese prospective study reported that if a targeted biopsy from a non-pedunculated polyp reveals desmoplastic reaction, the positive predictive value of deep submucosal invasion is high and surgery should be considered (41).

All of the abovementioned visual classifications suggest that we should thoroughly evaluate pit and vessel pattern, lesion morphology, as well as specific areas of concern (pseudodepression, demarcated areas, nodules,…), and that in the majority of cases visual diagnosis will suffice (42). However, distinguishing superficial invasion from deeply invading lesions or from lesions that may harbour negative prognostic features, remains a challenge even in expert hands. Computer aided detection and artificial intelligence models are currently being developed, which will hopefully aid us in improving patient selection in the very near future.

Primary resection

Large colorectal polyps

For diminutive polyps (<5mm) and sessile lesions 6-9mm, cold snare resection is regarded as the current treatment of choice, whereas hot snare polypectomy is still suggested for the removal of polyps 10-19mm (27). Submucosal injection should be considered for the latter subgroup of polyps, improving resection efficacy and safety. For these larger sessile or flat colorectal lesions, EMR is the current first-line therapy in most Western centers. A recent Belgian retrospective analysis (n=193, median lesion size 25mm) showed that EMR led to high rates of complete endoscopic (95.7%) and curative resection (90.3%) (43). Furthermore, adequate lesion selection resulted in a low need for adjunctive surgery due to submucosal invasive cancer (3.2%). Immediate adverse events occurred in 2.4% of patients (bleeding/perforation), whereas 7.3% (n=12) experienced delayed bleeding. In a bench-mark prospective evaluation of EMR in lesions 20mm or greater in size, polyps were removed effectively in 89.2% of patients and 83.7% avoided surgery (44). In both cohorts, lesion size > 40mm was identified as an independent risk factor for recurrent disease, with recurrence rates of 16.2% and 20% respectively. New developments in the field of EMR have improved outcomes, such as increased en-bloc resection rates with precut-EMR (45), reduced lesion recurrence following underwater EMR (46) and implementation of thermal ablation of mucosal defect margins (47,48). However, lack of en-bloc

Table 1. — **Published articles comparing safety and efficacy of EMR with ESD for colorectal lesions**

Author, year (ref)	Country	Inclusion criteria	No. of patients	Design	Lesions size	En-bloc resection	Perforation	Local recurrence	Adjunctive surgery
Iizuka, 2009 (48)	Japan	LST ≥20mm	83 EMR 38 ESD	Retrospective, Non-matched	31±17mm 39±20mm (p<0.05)	54% 61% (p=0.516)	1% 8% (p=0.056)	NR	8% 24% (p<0.05)
Inoue, 2021 (49)	Japan	LST 20-30mm	125 EMR^ 306 ESD	Retrospective, matched°	22.9±3.6mm 24.7±3.7mm	61% 99%	0% 3.6%	2.1% 0%	2.4% 6.2%
Jung, 2019 (50)	Korea	Advanced LSTs#	88 EMR 119 ESD	Retrospective, Non-matched	22.3±9.0mm 34.3±11.6mm	70.5% 87.4%	0% 2.5%	NR	NR
Kobayashi, 2012 (51)	Japan	NA	56 EMR 28 ESD	Prospective, matched	25±9.0mm 27±10mm (NS)	37.5% 92.9% (p<0.001)	0% 10.7% (p=0.013)	12% 0.0% (p=0.008)	1.8% 0% (NS)
Lee, 2012 (52)	Korea	LST ≥20mm	69 EMR* 314 ESD	Retrospective, Non-matched	23.5±5.6mm 28.9±12.7mm (p=0.004)	65.2% 92.7% (p=0.004)	2.9% 8.0% (p=0.006)	3.1% 0.8% (p=0.303)	1.5% 8.3%
Osera, 2017 (53)	Japan	LST >10mm	275 EMR 382 ESD	Retrospective, Non-matched	NR	NR 84.5%	NR 4.7%	0.4% 0.5%	NR
Saito, 2010 (54)	Japan	LST ≥20mm	228 EMR 145 ESD	Retrospective, Non-matched	28±8mm 37±14mm (p<0.001)	33% 84% (p<0.001)	1.3% 6.2% (NS)	14% 2% (p<0.001)	1.3% 0% (NS)
Soliman, 2018 (55)	France	LST ≥20mm	217 EMR 157 ESD	Retrospective, Non-matched	34.3±15.8mm 50.0±24.7mm (p<0.001)	26.3% 87.3% (p<0.001)	2.3% 5.7% (p=0.08)	15.2% 7.6% (p=0.026)	NR
Tajika, 2011 (56)	Japan	LST ≥20mm	104 EMR 85 ESD	Retrospective, Non-matched	25.5±6.8mm 31.6±9.0mm (p<0.001)	48.1% 83.5% (p<0.001)	0% 5.9% (p=0.040)	15.4% 1.2% (p=0.002)	2.9% 1.2% (NS)
Terasaki, 2012 (57)	Japan	LST >20mm	108 EMR* 91 ESD	Retrospective, Non-matched	37.4±17.7mm 42.1±17.1mm (p=0.002)	NR	1.9% 0% (NS)	12.1% 0% (p=0.016)	0.9% 8.2% (NS)

EMR: endoscopic mucosal resection, ESD: endoscopic submucosal dissection, LST: lateral spreading tumor, NR: not reported, NS: non-significant. # Only lateral spreading tumors with advanced histology were included. *Piecemeal endoscopic mucosal resection. ^Underwater endoscopic mucosal resection. ° Propensity score-matched design.

histopathological evaluation and increased recurrence risk following piecemeal resection, have remained the Achilles' heel of EMR. Piecemeal resection has not only been associated with benign recurrence, also higher rates of malignant recurrence have been seen when compared to en-bloc resection (4.3% vs. 0%, HR 11.4; 95% CI 0.48-273) (49). Conversely, ESD has been shown to be safe and efficacious over time, even in the context of extremely large lesions (50).

Various studies have compared the outcomes of EMR with ESD, with a meta-analysis of 6 studies showing higher en-bloc resection rates and fewer recurrences over time for ESD, at the cost of longer procedure time. Although considerable heterogeneity was seen in this particular study for other outcomes, procedure-related complications seemed similar with moderate heterogeneity amongst studies (p=0.15, I^2=43%) (51). Articles comparing safety and efficacy of EMR vs. ESD for colorectal lesions are summarized in Table 1, yet show low overall methodological quality with underrepresentation of the Western hemisphere (52-61). More prospective Western data are however underway, with preliminary results from a large French randomized controlled trial (n=359) confirming previously mentioned outcomes. This trial showed a significantly lower 6-month recurrence rate when comparing ESD with piecemeal-EMR for granular LSTs (0.6% vs. 5.1%, p=0.019), with similar complication rates (62).

In 2018, a large-scale cost-effectiveness analysis showed that ESD was more effective and less expensive than wide-field EMR, by preventing 19 surgeries per 1000 cases (63). ESD was only deemed cost effective amongst higher risk rectal lesions, as only a limited number of additional surgeries were prevented if universal ESD was implemented. Two more recent studies in their turn have showed favourable cost-effectiveness for universal ESD, being performed for all LSTs larger than 20mm, when compared to piecemeal-EMR and/or selective ESD (64,65). All three studies should however be put into perspective with national reimbursement policies, as in most settings ESD will lead to higher individual procedural costs. Over time reduced costs and superior cost-effectiveness are seen for ESD, mainly driven by the prevention of recurrence, lower need for surgical interventions and reduced need for endoscopic surveillance.

Early carcinoma and submucosal invasive cancer

Identification of these high risk lesions is of the greatest importance, directing us towards selecting the most appropriate endoscopic technique for each individual patient, preventing local recurrence and non-curative resections. High-grade dysplasia (HGD) and need for piecemeal resection, as well as lesion size itself, have been associated with local recurrence (26,37,43,44,66). Whereas non-curative resection depends on the presence of advanced histology, which is found in 5.2% to 6.6% of polyps smaller than 10mm, increasing up to 50%, depending on dimensions and morphology (44,67,68). It has therefore been suggested that en-bloc resection by ESD should be preferred over EMR when: 1) lesion size exceeds 20 mm, 2) visual endoscopic diagnosis suggesting high-grade dysplasia, in-situ carcinoma or (superficial) submucosal invasion (Sm1), and/or depending on 3) location (dentate line involvement, ileocecal valve, etc) (37,66,69). Specifically in lesions with signs of superficial submucosal invasion (JNET 2B, Kudo V_1), en-bloc endoscopic resection techniques facilitate adequate histological diagnosis, whereas (piecemeal-)EMR can be considered in the absence of worrisome features. In cases where deeper invasion is suspected, oncological work-up and surgical treatment should be considered.

Regarding surgical outcomes, only a handful of studies have compared surgery with ESD. A 2012 retrospective study compared transanal endoscopic microsurgery (TEM) with ESD in the context of non-invasive rectal neoplasia (70). Sixty-three cases were included, showing almost identical en-bloc and R0 resection rates, with lower procedure time and hospital stay in favour of ESD. In the same year, a comparative analysis was published with data from eight Dutch centers, showing more adverse events and longer hospital stay in the surgical group (71). Furthermore, a relatively high recurrence rate of 10.2% was seen for TEM, making us wonder whether high-definition endoscopes are perhaps better suited for such resections and how ESD would compare in a randomized trial. Cost-effectiveness analyses have furthermore shown that ESD led to fewer costs when compared to colorectal surgery, perhaps fuelled by outcomes such as hospital stay and complication rates (72). Although prospective confirmation is being sought (73,74), the current evidence suggests that surgery should only be considered for lesions not-amendable for endoscopic resection and/or when deep invasion is suspected.

Neuroendocrine neoplasms

Neuroendocrine neoplasms (NENs) develop from the neuroendocrine cell system and may occur throughout the body, usually affecting both mucosa & submucosa. From 1973 until 2012, the incidence rate of NENs increased more than six-fold, with the highest incidence rates amongst gastroenteropancreatic NENs (75). Using the 2019 WHO classification for gastroenteropancreatic NENs, these subepithelial lesions can be subdivided in well-differentiated (G1 or G2) neuroendocrine tumors with a Ki-67 Index of <3% or ≥3%-20%, up to poorly differentiated neuroendocrine carcinomas (G3) with a Ki-67 Index of >20% (76). Most of the gastrointestinal NENs are detected in the stomach or rectum at routine endoscopy and efforts should be made to provide adequate tissue diagnosis of these subepithelial lesions using either bite-on-bite sampling, mucosal incision-assisted biopsy

(77) or for example EUS-guided fine-needle biopsy. It is generally accepted that all confirmed non-gastric NENs may benefit from resection, regardless of size (78).

A large nation-wide retrospective study in 2021 (n=310 NENs) showed that no lymph node invasion and/or distant metastases were seen in endoscopically-treated G1 NENs up to 20mm diameter (79). Whereas other studies have shown that G2 histology, greater lesion size, lesion depression and/or ulceration and lymphovascular invasion (80) are risk factors for developing metachronous metastatic disease (81,82). Although these data suggest that non-depressed rectal G1 NENs up to 20mm are amendable for endoscopic resection, improved complete resection rates have been seen when comparing ESD with conventional EMR (80,83), whereas modified EMR techniques seem to outperform conventional EMR (84-86). Due to the limitations of modified EMR (band ligation and cap- or incision-assisted EMR) regarding maximum lesion size, this technique seems an acceptable less-demanding option for rectal NENs less than 10mm in diameter.

For the endoscopic management of larger lesions, ESD should be considered due to higher chances of complete curative resection (78,85-87). As for pre-treated or fibrotic NENs, both ESD and endoscopic full-thickness resection (eFTR) seem most appropriate (88). Comparisons of ESD with TEM are scarce, with a recent propensity score-matched analysis showing fewer adverse events and shorter hospital stay in favour of ESD, at the cost of a lower R0-resection rate with increasing lesion size (89).

Large pedunculated polyps

Snare resection of large pedunculated lesions can be technically challenging and has been associated with a high risk of immediate and late post-resection bleeding. Pre-treatment with epinephrine injection and/or mechanical haemostasis in pedunculated polyps with head ≥ 20mm or a stalk ≥ 10mm in diameter has therefore been recommended (27). However, in some cases dimensions of the polyp head will not allow for (detachable) snare placement. In this specific context, ESD may prove useful in providing controlled step-by-step dissection of the stalk and securing immediate haemostasis. One of the first cohorts in 2013 showed similar efficacy and procedure times when comparing ESD with snare resection of large pedunculated lesions, with post-polypectomy bleeding occurring in 4.3% and 15% respectively (90). In 2021, a multicenter feasibility study was published, evaluating the efficacy and safety of ESD for large pedunculated polyps with wide stalks (91). In 28 out of 29 lesions (mean polyp size 39.7mm), en-bloc resection was achieved with no severe complications throughout the cohort. In the context of large pedunculated colorectal polyps, ESD seems most useful in situations where the polyp head dimensions does not allow (detachable) snare placement or when a wide stalk precludes adequate pre-emptive mechanical haemostasis.

Treatment of local recurrent lesions

Post-endoscopic mucosal resection

Colorectal residual/recurrent lesions after previous resection attempts may contain different degrees of fibrosis. As such, repeat en-bloc EMR can be extremely challenging. Piecemeal EMR furthermore holds a high risk of new recurrences over time, and complicates accurate pathological diagnosis. On the other hand, surgery could be considered overtreatment for pre-cancerous lesions or early cancers. ESD may provide a more effective, yet safer alternative for treatment of such recurrent lesions following EMR(92). A total of 9 studies have described the clinical outcomes of ESD for local residual/recurrent colorectal lesions (92-100) All studies but one, the most recent (2021, n=81 lesions), were performed in single, high-volume centres. This group, comprising one academic and 24 community hospitals with varying levels of experience in colorectal ESD, retrospectively reported en-bloc and R0 resection rates of 95.1% and 90.1% respectively. Incidence of delayed perforation and delayed bleeding were identical (2.5%), whereas no local recurrences occurred following rescue ESD (98). These results are in line with earlier studies (92-99). Remarkably, only the oldest study (n=30) had a prospective design (93). Due to the increased risk of fibrosis, additional tools and techniques should be considered to mitigate severe submucosal fibrosis, which may include the pocket-creation method or traction methods (4,101-104). Double clip and rubber band traction in particular have been evaluated in a 2020 French analysis of recurrent lesions, leading to en-bloc resection in 92.5% of cases (100). Also this paper suggests a significant learning curve regarding these challenging lesions.

ESD for recurrent lesions after EMR, can be applied safely and effectively and may avoid unnecessary surgery. Because of different degrees of fibrosis, we suggest it should be performed by endoscopists with a high level of skill and experience in colorectal ESD.

Anastomotic lesions

ESD can be used to treat gastrointestinal neoplasia even in the presence of severe submucosal fibrosis. However safety and efficacy of ESD for colorectal neoplasia located on the suture line of anastomosis has not been studied well. In the first place because anastomotic recurrence (AR) after curative resection of CRC is rare. One retrospective study with over 9000 patients suggests an AR rate of approximately 0.6%. Risk factors for AR are age, rectum, N stage, T stage, lymphovascular invasion and mucinous differentiation (105). The first small case series (3 patients), demonstrating feasibility

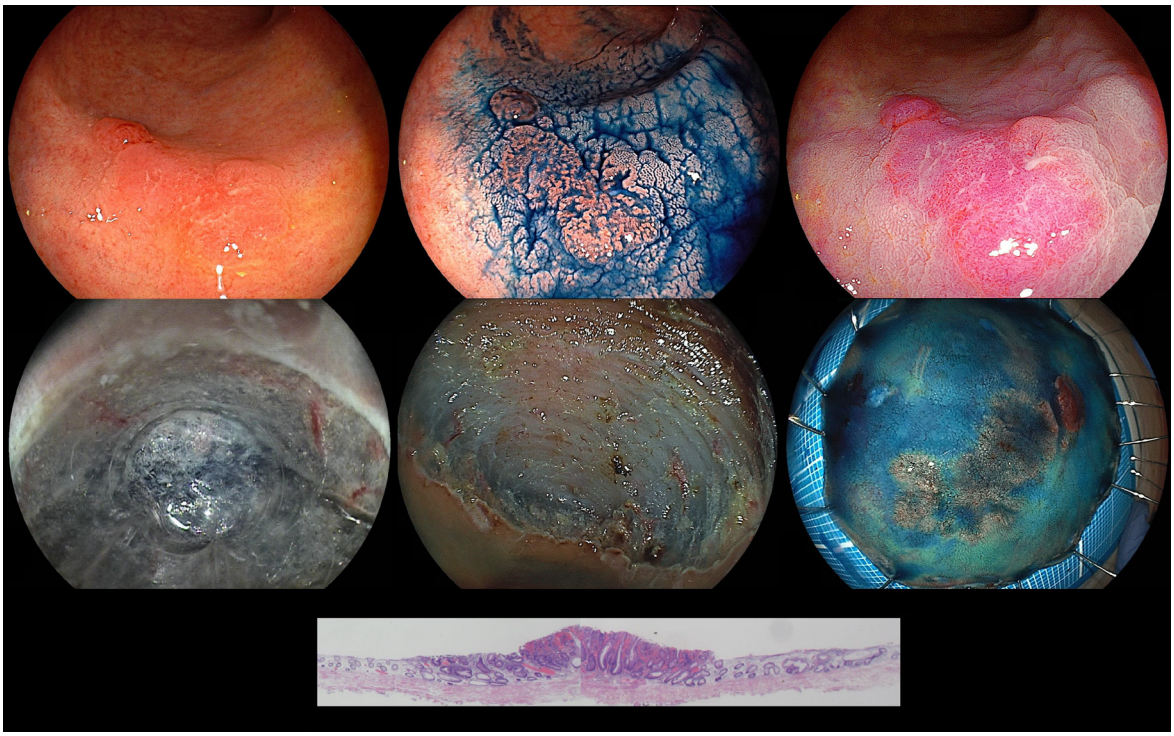

Figure 3. — Endoscopic submucosal dissection of an ulcerative colitis-associated neoplasia with extensive submucosal fibrosis. Upper left: White light endoscopic image showing a flat Paris 0-IIa+IIb lesion. Upper middle: Endoscopic examination with indigo carmine dye. Upper right: Endoscopic examination with linked color imaging (LCI). Lower left: Severe submucosal fibrosis during endoscopic submucosal dissection using the pocket-creation method. Lower middle: Final endoscopic image after complete endoscopic submucosal dissection.Lower right: Ex-vivo view of the en-bloc resection specimen. Micro-scopic image: Pathological evaluation confirmed well-differentiated adenocarcinoma localized to the mucosa (Tis) without lymphovascular invasion and negative resection margins. The mucosa surrounding the lesion revealed diffuse p53 expression similar to malignant mucosa, consistent with a colitis-associated neoplastic lesion (H&E staining, magnification: 1000x).

of ESD in this specific setting, dates back from 2014. The authors spared the edges of the neoplasia directly on top of the suture line in order to avoid potential delayed perforation. Instead this part was removed by hemostatic forceps, leading to recurrence in one patient (106). Only one similar video case was published afterwards (107). Two independent retrospective series of both 11 patients were published in 2020. The first group observed en-bloc resection in almost 90% and R0 resection in 67% of cases, despite technically challenging procedures in the presence of severe submucosal fibrosis (108). Compared to previous studies of colorectal ESD for recurrent tumors after endoscopic resection, the en-bloc resection rate was comparable with a lower R0 resection rate (67-84%) (96,97,99).The second group reports slightly lower success rates with en-bloc resection in 64% and R0 resection in 55% (109). Adverse event rates were similar in both groups: only one patient in each group experienced delayed bleeding. No perforations was seen. In contrast to the first report by Horii, et al. the edge of neoplasia directly on top of the surgical anastomosis was not treated differently, classic ESD technique was applied throughout these procedures (108,109). Eventual suture material was removed before ESD, by peeling of the surrounding tissue (109,110).

Because of this poor body of nonrandomized evidence, today no clear indications for ESD of AR exists. ESD can be considered for AR lesions with a negligible risk of lymph node metastasis, as a minimally alternative to surgical reintervention. It should however be reserved for high-volume medical centers and endoscopists with an expert level of skill and experience.

Endoscopic resections in patients with inflammatory bowel disease

Patients with ulcerative colitis (UC) exhibit an increased risk of developing dysplastic lesions and colorectal cancer due to chronic inflammation (111). These lesions may prove challenging to resect when compared to non-IBD setting owing to flat non-polypoid morphology, extensive fibrosis, large size or difficult delineation (Figure 3). Endoscopic treatment for both polypoid and non-polypoid neoplastic lesions in UC can be considered when distinct margins are present and in absence of signs of deep mucosal invasion (112). Both EMR and ESD have become key modalities in the management of endoscopically resectable UC-associated neoplasia (UCAN). EMR is an adequate technique for most large colorectal polyps, but it relies on adequate lifting of the submucosal layer. Non-lifting can reflect invasiveness, but it also occurs in submucosal fibrosis, which is largely present in UC. As such, EMR may prove ineffective for large lesions due to submucosal fibrosis,

which can be overcome by ESD. Moreover, ESD provides superior specimen quality for histological evaluation and circumferential cutting with a knife provides more accurate excision with negative margins compared to capturing the lesion with a snare (113).

Several studies performed by expert centres over the last 2 decades support the feasibility, safety and efficacy of ESD for the treatment of UCAN (114-122). A pooled analysis of the 9 available studies (5 Asian and 4 European groups, n=244 lesions), shows en-bloc and complete resection rates of respectively 86.9% and 77.9%. In terms of safety, perforation rates were 2.4%, while delayed bleeding occurred in 7.8%, the latter appearing high, but with 2 outliers, both in European studies (116,121). Besides delayed bleeding, there were no important discrepancies between European and Asian studies. Local recurrence rates seem relatively high at 6.5%, while metachronous lesion rates may reach 6.6%. For now, long-term outcome data are still lacking. ESD for UCAN, performed by endoscopists with a high level of skill and experience, can be applied safely and effectively and may avoid unnecessary colectomy. We recommend to perform ESD for UCAN after careful discussion with the patient, in collaboration with a multidisciplinary IBD team (including endoscopists, IBD specialists, surgeons and pathologists specialized in IBD). Since no adequate assessment has been reported on the long-term outcomes, careful follow-up should be organized to detect local recurrence and metachronous lesions.

Conclusions

The development of ESD has improved the outcomes after endoscopic resection of (pre-)malignant colorectal lesions and has partially bridged the gap between endoscopy and surgery. Not only has the evidence increased in the context of ESD for large colorectal polyps, it has also found its way into our guidelines for the treatment of NENs and/or recurrent lesions, and seems a promising alternative for the treatment of large pedunculated lesions. ESD can also be applied in more challenging situations, such as in pre-treated lesions, post-surgical context and in patients with IBD, although this requires a high level of skill and expertise. In this review we have described the different indications for ESD and attempted to define its place within our current endoscopic armamentarium. For both non-expert and expert endoscopists, knowledge about ESD indications, patient selection and therapeutic alternatives, remains crucial in the care for patients with colorectal neoplasia.

Funding

None

Conflict of interest

Michiel Bronswijk received grants from Boston Scientific, is supported by the klinische onderzoeks- en opleidingsraad (KOOR) – KU Leuven and has consultancy agreements with Dekra and Prion Medical – Taewoong Yoshikazu Hayashi has received honoraria from Fujifilm Corp. Hironori Yamamoto has patents for the double-balloon endoscope produced by Fujifilm Corp. He also serves as a consultant for and has received honoraria, grants, and royalties from Fujifilm Corp.

References

1. YAMAMOTO H, KOIWAI H, YUBE T, ISODA N, SATO Y, SEKINE Y, *et al.* A successful single-step endoscopic resection of a 40 millimeter flat-elevated tumor in the rectum: endoscopic mucosal resection using sodium hyaluronate. *Gastrointest Endosc*. 1999, **50(5)**: 701-4.
2. ONO H, KONDO H, GOTODA T, SHIRAO K, YAMAGUCHI H, SAITO D, *et al.* Endoscopic mucosal resection for treatment of early gastric cancer. *Gut*. 2001, **48(2):** 225-9.
3. OHKUWA M, HOSOKAWA K, BOKU N, OHTU A, TAJIRI H, YOSHIDA S. New endoscopic treatment for intramucosal gastric tumors using an insulated-tip diathermic knife. *Endoscopy*. 2001, **33(3)**: 221-6.
4. YAMAMOTO H, KAWATA H, SUNADA K, SASAKI A, NAKAZAWA K, MIYATA T, *et al.* Successful en-bloc resection of large superficial tumors in the stomach and colon using sodium hyaluronate and small-caliber-tip transparent hood. *Endoscopy*. 2003, **35(8)**: 690-4.
5. YAMAMOTO H, SEKINE Y, HIGASHIZAWA T, KIHIRA K, KANEKO Y, HOSOYA Y, *et al.* Successful en bloc resection of a large superficial gastric cancer by using sodium hyaluronate and electrocautery incision forceps. *Gastrointest Endosc*. 2001, **54(5)**: 629-32.
6. INOUE H, MINAMI H, KOBAYASHI Y, SATO Y, KAGA M, SUZUKI M, *et al.* Peroral endoscopic myotomy (POEM) for esophageal achalasia. *Endoscopy*. 2010, **42(4)**: 265-71.
7. PASRICHA PJ, HAWARI R, AHMED I, CHEN J, COTTON PB, HAWES RH, *et al.* Submucosal endoscopic esophageal myotomy: a novel experimental approach for the treatment of achalasia. *Endoscopy*. 2007, **39(9)**: 761-4.
8. XU MD, CAI MY, ZHOU PH, QIN XY, ZHONG YS, CHEN WF, *et al.* Submucosal tunneling endoscopic resection: a new technique for treating upper GI submucosal tumors originating from the muscularis propria layer (with videos). *Gastrointest Endosc*. 2012, **75(1)**: 195-9.
9. YAMAMOTO H. Technology insight: endoscopic submucosal dissection of gastrointestinal neoplasms. *Nat Clin Pract Gastroenterol Hepatol*. 2007, **4(9)**: 511-20.
10. SAITO Y, FUJII T, KONDO H, MUKAI H, YOKOTA T, KOZU T, *et al.* Endoscopic treatment for laterally spreading tumors in the colon. *Endoscopy*. 2001, **33(8)**: 682-6.
11. YAMAMOTO H, SUNADA K, MIYATA T, SEKINE Y, KITA H, IWAMOTO M, *et al.* Endoscopic submucosal dissection using sodium hyaluronate for large superficial tumors in the colon. Digestive *Endoscopy*. 2004, **16(2)**: 178-81.
12. FUJISHIRO M, YAHAGI N, KAKUSHIMA N, KODASHIMA S, MURAKI Y, ONO S, *et al.* Outcomes of endoscopic submucosal dissection for colorectal epithelial neoplasms in 200 consecutive cases. *Clin Gastroenterol Hepatol*. 2007, **5(6)**: 678-83; quiz 45.
13. MIURA Y, HAYASHI Y, LEFOR AK, OSAWA H, YAMAMOTO H. The pocket-creation method of ESD for gastric neoplasms. *Gastrointest Endosc*. 2016, **83(2)**: 457-8.
14. SPADACCINI M, HASSAN C, MASELLI R, D'AMICO F, LAMONACA L, CRAVIOTTO V, *et al.* Efficacy and safety of SIC-8000 (Eleview®) for submucosal injection for endoscopic mucosal resection and endoscopic submucosal dissection in an in vivo porcine model. *Dig Liver Dis*. 2018, **50(3)**: 260-6.
15. OKA S, TANAKA S, TAKATA S, KANAO H, CHAYAMA K. Usefulness and safety of SB knife Jr in endoscopic submucosal dissection for colorectal tumors. *Dig Endosc*. 2012, 24 Suppl 1: 90-5.
16. BORDILLON P, PIOCHE M, WALLENHORST T, RIVORY J, LEGROS R, ALBOUYS J, *et al.* Double-clip traction for colonic endoscopic submucosal dissection: a multicenter study of 599 consecutive cases (with video). *Gastrointest Endosc*. 2021, **94(2)**: 333-43.
17. YAMASHINA T, NEMOTO D, HAYASHI Y, FUKUDA H, OKADA M, TAKEZAWA T, *et al.* Prospective randomized trial comparing the pocket-creation method and conventional method of colorectal endoscopic submucosal dissection. *Gastrointest Endosc*. 2020, **92(2)**: 368-79.
18. TAKEZAWA T, HAYASHI Y, SHINOZAKI S, SAGARA Y, OKADA M, KOBAYASHI Y, *et al.* The pocket-creation method facilitates colonic endoscopic submucosal dissection (with video). *Gastrointest Endosc*. 2019, **89(5)**: 1045-53.

19. SHINOZAKI S, HAYASHI Y, MIURA Y, YANO T, LEFOR AK, YAMAMOTO H. Effectiveness and safety of endoscopic submucosal dissection using the pocket creation method in the Japanese population: a systematic review and meta-analysis. *Endosc Int Open.* 2022, **10(5)**: E694-e702.
20. HAYASHI Y, SUNADA K, TAKAHASHI H, SHINHATA H, LEFOR AT, TANAKA A, *et al.* Pocket-creation method of endoscopic submucosal dissection to achieve en bloc resection of giant colorectal subpedunculated neoplastic lesions. *Endoscopy*. 2014, 46 Suppl 1 UCTN: E421-2.
21. HAYASHI Y, MIURA Y, YAMAMOTO H. Pocket-creation method for the safe, reliable, and efficient endoscopic submucosal dissection of colorectal lateral spreading tumors. *Dig Endosc.* 2015, **27(4)**: 534-5.
22. KUDO S, TAMURA S, NAKAJIMA T, YAMANO H, KUSAKA H, WATANABE H. Diagnosis of colorectal tumorous lesions by magnifying endoscopy. *Gastrointest Endosc*. 1996, **44(1)**: 8-14.
23. TOGASHI K, KONISHI F, ISHIZUKA T, SATO T, SENBA S, KANAZAWA K. Efficacy of magnifying endoscopy in the differential diagnosis of neoplastic and non-neoplastic polyps of the large bowel. *Dis Colon Rectum*. 1999, **42(12)**: 1602-8.
24. KOMEDA Y, KASHIDA H, SAKURAI T, ASAKUMA Y, TRIBONIAS G, NAGAI T, *et al.* Magnifying Narrow Band Imaging (NBI) for the Diagnosis of Localized Colorectal Lesions Using the Japan NBI Expert Team (JNET) Classification. *Oncology*. 2017, 93 Suppl 1: 49-54.
25. SANO Y, TANAKA S, KUDO SE, SAITO S, MATSUDA T, WADA Y, *et al.* Narrow-band imaging (NBI) magnifying endoscopic classification of colorectal tumors proposed by the Japan NBI Expert Team. *Dig Endosc.* 2016, **28(5)**: 526-33.
26. VANELLA G, COLUCCIO C, ANTONELLI G, ANGELETTI S, MICHELI F, BARBATO A, *et al.* Improving assessment and management of large non-pedunculated colorectal lesions in a Western center over 10 years: lessons learned and clinical impact. *Endosc Int Open.* 2020, **8(10)**: E1252-e63.
27. FERLITSCH M, MOSS A, HASSAN C, BHANDARI P, DUMONCEAU JM, PASPATIS G, *et al.* Colorectal polypectomy and endoscopic mucosal resection (EMR): European Society of Gastrointestinal Endoscopy (ESGE) Clinical Guideline. *Endoscopy*. 2017, **49(3)**: 270-97.
28. Update on the paris classification of superficial neoplastic lesions in the digestive tract. *Endoscopy*. 2005, **37(6)**: 570-8.
29. KUDO S. Endoscopic mucosal resection of flat and depressed types of early colorectal cancer. *Endoscopy*. 1993, **25(7):** 455-61.
30. LAMBERT R, KUDO SE, VIETH M, ALLEN JI, FUJII H, FUJII T, *et al.* Pragmatic classification of superficial neoplastic colorectal lesions. *Gastrointest Endosc*. 2009, **70(6)**: 1182-99.
31. BOGIE RMM, VELDMAN MHJ, SNIJDERS L, WINKENS B, KALTENBACH T, MASCLEE AAM, *et al.* Endoscopic subtypes of colorectal laterally spreading tumors (LSTs) and the risk of submucosal invasion: a meta-analysis. *Endoscopy*. 2018, **50(3)**: 263-82.
32. KOYAMA Y, FUKUZAWA M, KONO S, MADARAME A, MORISE T, UCHIDA K, *et al.* Diagnostic efficacy of the Japan NBI Expert Team classification with dual-focus magnification for colorectal tumors. *Surg Endosc*. 2022, **36(7)**: 5032-40.
33. BACKES Y, SCHWARTZ MP, TER BORG F, WOLFHAGEN FHJ, GROEN JN, DE VOS TOT NEDERVEEN CAPPEL WH, *et al.* Multicentre prospective evaluation of real-time optical diagnosis of T1 colorectal cancer in large non-pedunculated colorectal polyps using narrow band imaging (the OPTICAL study). *Gut*. 2019, **68(2):** 271.
34. VOSKO S, SHAHIDI N, SIDHU M, VAN HATTEM WA, BAR-YISHAY I, SCHOEMAN S, *et al.* Optical Evaluation for Predicting Cancer in Large Nonpedunculated Colorectal Polyps Is Accurate for Flat Lesions. *Clin Gastroenterol Hepatol*. 2021, **19(11):** 2425-34.e4.
35. SHIMURA T, EBI M, YAMADA T, HIRATA Y, NISHIWAKI H, MIZUSHIMA T, *et al.* Magnifying chromoendoscopy and endoscopic ultrasonography measure invasion depth of early stage colorectal cancer with equal accuracy on the basis of a prospective trial. *Clin Gastroenterol Hepatol.* 2014, **12(4)**: 662-8.e1-2.
36. MATSUMOTO T, HIZAWA K, ESAKI M, KURAHARA K, MIZUNO M, HIRAKAWA K, *et al.* Comparison of EUS and magnifying colonoscopy for assessment of small colorectal cancers. *Gastrointest Endosc*. 2002, **56(3)**: 354-60.
37. PIMENTEL-NUNES P, LIBÂNIO D, BASTIAANSEN BAJ, BHANDARI P, BISSCHOPS R, BOURKE MJ, *et al.* Endoscopic submucosal dissection for superficial gastrointestinal lesions: European Society of Gastrointestinal Endoscopy (ESGE) Guideline - Update 2022. *Endoscopy*. 2022.
38. GILLARD V. Evaluation of polyps by endoscopic ultrasonography (eus): implication for endotherapy. *Acta Gastroenterol Belg.* 1999, **62(2):** 196-9.
39. POUW RE, BISSCHOPS R, GECSE KB, DE HERTOGH G, IACUCCI M, RUTTER M, *et al.* Endoscopic tissue sampling - Part 2: Lower gastrointestinal tract. European Society of Gastrointestinal Endoscopy (ESGE) Guideline. *Endoscopy*. 2021, **53(12)**: 1261-73.
40. KUROHA M, SHIGA H, KANAZAWA Y, NAGAI H, HANDA T, ICHIKAWA R, *et al.* Factors Associated with Fibrosis during Colorectal Endoscopic Submucosal Dissection: Does Pretreatment Biopsy Potentially Elicit Submucosal Fibrosis and Affect Endoscopic Submucosal Dissection Outcomes? *Digestion*. 2021, **102(4)**: 590-8.
41. KIMURA R, FUJIMORI T, ICHIKAWA K, AJIOKA Y, UENO H, OHKURA Y, *et al.* Desmoplastic reaction in biopsy specimens of early colorectal cancer: a Japanese prospective multicenter study. *Pathol Int.* 2012, **62(8)**: 525-31.
42. SHINOZAKI S, HAYASHI Y, LEFOR AK, YAMAMOTO H. What is the best therapeutic strategy for colonoscopy of colorectal neoplasia? Future perspectives from the East. *Dig Endosc.* 2016, **28(3)**: 289-95.
43. CHAOUI I, DEMEDTS I, ROELANDT P, WILLEKENS H, BISSCHOPS R. Endoscopic mucosal resection of colorectal polyps: results, adverse events and two-year outcome. *Acta Gastroenterol Belg.* 2022, **85(1)**: 47-55.
44. MOSS A, BOURKE MJ, WILLIAMS SJ, HOURIGAN LF, BROWN G, TAM W, *et al.* Endoscopic mucosal resection outcomes and prediction of submucosal cancer from advanced colonic mucosal neoplasia. *Gastroenterology*. 2011, **140(7)**: 1909-18.
45. OH CK, CHO YW, CHOI IH, LEE HH, LIM CH, KIM JS, *et al.* Comparison of precutting endoscopic mucosal resection and endoscopic submucosal dissection for large (20-30 mm) flat colorectal lesions. *J Gastroenterol Hepatol.* 2022, **37(3)**: 568-75.
46. TAN DJH, NG CH, LIM XC, LIM WH, YUEN LZH, KOH JH, *et al.* Is underwater endoscopic mucosal resection of colon polyps superior to conventional techniques? A network analysis of endoscopic mucosal resection and submucosal dissection. *Endosc Int Open*. 2022, **10(1)**: E154-e62.
47. KLEIN A, TATE DJ, JAYASEKERAN V, HOURIGAN L, SINGH R, BROWN G, *et al.* Thermal Ablation of Mucosal Defect Margins Reduces Adenoma Recurrence After Colonic Endoscopic Mucosal Resection. *Gastroenterology*. 2019, **156(3)**: 604-13.e3.
48. SIDHU M, SHAHIDI N, GUPTA S, DESOMER L, VOSKO S, ARNOUT VAN HATTEM W, *et al.* Outcomes of Thermal Ablation of the Mucosal Defect Margin After Endoscopic Mucosal Resection: A Prospective, International, Multicenter Trial of 1000 Large Nonpedunculated Colorectal Polyps. *Gastroenterology*. 2021, **161(1)**: 163-70.e3.
49. MEHTA N, ABUSHAHIN A, SADAPS M, ALOMARI M, VARGO J, PATIL D, *et al.* Recurrence with malignancy after endoscopic resection of large colon polyps with high-grade dysplasia: incidence and risk factors. *Surg Endosc*. 2021, **35(6):** 2500-8.
50. HAYASHI Y, SHINOZAKI S, SUNADA K, SATO H, MIURA Y, INO Y, *et al.* Efficacy and safety of endoscopic submucosal dissection for superficial colorectal tumors more than 50 mm in diameter. *Gastrointest Endosc*. 2016, **83(3)**: 602-7.
51. WANG J, ZHANG XH, GE J, YANG CM, LIU JY, ZHAO SL. Endoscopic submucosal dissection vs endoscopic mucosal resection for colorectal tumors: a meta-analysis. *World J Gastroenterol.* 2014, **20(25)**: 8282-7.
52. IIZUKA H, OKAMURA S, ONOZATO Y, ISHIHARA H, KAKIZAKI S, MORI M. Endoscopic submucosal dissection for colorectal tumors. *Gastroenterol Clin Biol.* 2009, **33(10-11)**: 1004-11.
53. INOUE T, NAKAGAWA K, YAMASAKI Y, SHICHIJO S, KANESAKA T, MAEKAWA A, *et al.* Underwater endoscopic mucosal resection versus endoscopic submucosal dissection for 20-30 mm colorectal polyps. *J Gastroenterol Hepatol*. 2021, **36(9)**: 2549-57.
54. JUNG JS, HONG JY, OH HH, KWEON SS, LEE J, KIM SW, *et al.* Clinical outcomes of endoscopic resection for colorectal laterally spreading tumors with advanced histology. *Surg Endosc.* 2019, **33(8)**: 2562-71.
55. KOBAYASHI N, YOSHITAKE N, HIRAHARA Y, KONISHI J, SAITO Y, MATSUDA T, *et al.* Matched case-control study comparing endoscopic submucosal dissection and endoscopic mucosal resection for colorectal tumors. *J Gastroenterol Hepatol.* 2012, **27(4)**: 728-33.
56. LEE EJ, LEE JB, LEE SH, YOUK EG. Endoscopic treatment of large colorectal tumors: comparison of endoscopic mucosal resection, endoscopic mucosal resection-precutting, and endoscopic submucosal dissection. *Surg Endosc*. 2012, **26(8)**: 2220-30.
57. OSERA S, IKEMATSU H, FUJII S, HORI K, OONO Y, YANO T, *et al.* Endoscopic treatment outcomes of laterally spreading tumors with a skirt (with video). *Gastrointest Endosc*. 2017, **86(3)**: 533-41.
58. SAITO Y, FUKUZAWA M, MATSUDA T, FUKUNAGA S, SAKAMOTO T, URAOKA T, *et al.* Clinical outcome of endoscopic submucosal dissection versus endoscopic mucosal resection of large colorectal tumors as determined by curative resection. *Surg Endosc.* 2010, **24(2)**: 343-52.
59. SOLIMAN H, BRIEAU B, GUILLAUMOT MA, LEBLANC S, BARRET M, CAMUS M, *et al.* Invasive pit pattern, macronodule and depression are predictive factors of submucosal invasion in colorectal laterally spreading tumours from a Western population. *United European Gastroenterol J.* 2018, **6(10)**: 1569-77.
60. TAJIKA M, NIWA Y, BHATIA V, KONDO S, TANAKA T, MIZUNO N, *et al.* Comparison of endoscopic submucosal dissection and endoscopic

mucosal resection for large colorectal tumors. *Eur J Gastroenterol Hepatol.* 2011, **23(11)**: 1042-9.
61. TERASAKI M, TANAKA S, OKA S, NAKADOI K, TAKATA S, KANAO H, *et al.* Clinical outcomes of endoscopic submucosal dissection and endoscopic mucosal resection for laterally spreading tumors larger than 20 mm. *J Gastroenterol Hepatol.* 2012, **27(4)**: 734-40.
62. JACQUES J, WALLENHORST T, CHEVAUX J-B, LÉPILLIEZ DV, CHAUSSADE S, RIVORY J, *et al.* ENDOSCOPIC SUBMUCOSAL DISSECTION (ESD) VERSUS PIECE-MEAL ENDOSCOPIC MUCOSAL RESECTION (PM-EMR) FOR LARGE LATERALLY SPREADING LESIONS: FRENCH RANDOMIZED CONTROLLED TRIAL RESECT-COLON. *Gastrointestinal Endoscopy*. 2022, **95(6)**: AB138.
63. BAHIN FF, HEITMAN SJ, RASOULI KN, MAHAJAN H, MCLEOD D, LEE EYT, *et al.* Wide-field endoscopic mucosal resection versus endoscopic submucosal dissection for laterally spreading colorectal lesions: a cost-effectiveness analysis. *Gut*. 2018, **67(11)**: 1965-73.
64. STÉPHANE S, TIMOTHÉE W, JÉRÉMIE A, RAPHAEL O, MARTIN D, EMMANUELLE P, *et al.* Endoscopic submucosal dissection or piecemeal endoscopic mucosal resection for large superficial colorectal lesions: A cost effectiveness study. *Clin Res Hepatol Gastroenterol.* 2022, **46(6)**: 101969.
65. SEKIGUCHI M, IGARASHI A, MIZUGUCHI Y, TAKAMARU H, YAMADA M, SAKAMOTO T, *et al.* Cost-effectiveness analysis of endoscopic resection for colorectal laterally spreading tumors: Endoscopic submucosal dissection versus piecemeal endoscopic mucosal resection. *Dig Endosc.* 2022, **34(3)**: 553-68.
66. TANAKA S, KASHIDA H, SAITO Y, YAHAGI N, YAMANO H, SAITO S, *et al.* Japan Gastroenterological Endoscopy Society guidelines for colorectal endoscopic submucosal dissection/endoscopic mucosal resection. *Dig Endosc.* 2020, **32(2)**: 219-39.
67. IWAI T, IMAI K, HOTTA K, ITO S, YAMAGUCHI Y, KAWATA N, *et al.* Endoscopic prediction of advanced histology in diminutive and small colorectal polyps. *J Gastroenterol Hepatol.* 2019, **34(2)**: 397-403.
68. SHIMODATE Y, ITAKURA J, MIZUNO M, TAKEZAWA R, KOBAYASHI M, YAMAZAKI T, *et al.* Factors Associated with possibly Inappropriate Histological Evaluation of Excised Specimens in Cold-snare Polypectomy for Small Colorectal Polyps. *J Gastrointestin Liver Dis.* 2018, **27(1):** 25-30.
69. SAKAMOTO H, HAYASHI Y, MIURA Y, SHINOZAKI S, TAKAHASHI H, FUKUDA H, *et al.* Pocket-creation method facilitates endoscopic submucosal dissection of colorectal laterally spreading tumors, non-granular type. *Endosc Int Open*. 2017, **5(2)**: E123-e9.
70. PARK SU, MIN YW, SHIN JU, CHOI JH, KIM YH, KIM JJ, *et al.* Endoscopic submucosal dissection or transanal endoscopic microsurgery for nonpolypoid rectal high grade dysplasia and submucosa-invading rectal cancer. *Endoscopy*. 2012, **44(11)**: 1031-6.
71. BARENDSE RM, VAN DEN BROEK FJ, VAN SCHOOTEN J, BEMELMAN WA, FOCKENS P, DE GRAAF EJ, *et al.* Endoscopic mucosal resection vs transanal endoscopic microsurgery for the treatment of large rectal adenomas. *Colorectal Dis.* 2012, **14(4)**: e191-6.
72. DAHAN M, PAULIAT E, LIVA-YONNET S, BRISCHOUX S, LEGROS R, TAILLEUR A, *et al.* What is the cost of endoscopic submucosal dissection (ESD)? A medico-economic study. *United European Gastroenterol J.* 2019, **7(1)**: 138-45.
73. DEKKERS N, BOONSTRA JJ, MOONS LMG, HOMPES R, BASTIAANSEN BA, TUYNMAN JB, *et al.* Transanal minimally invasive surgery (TAMIS) versus endoscopic submucosal dissection (ESD) for resection of non-pedunculated rectal lesions (TRIASSIC study): study protocol of a European multicenter randomised controlled trial. *BMC Gastroenterol*. 2020, **20(1)**: 225.
74. BACKES Y, MOONS LM, VAN BERGEIJK JD, BERK L, TER BORG F, TER BORG PC, *et al.* Endoscopic mucosal resection (EMR) versus endoscopic submucosal dissection (ESD) for resection of large distal non-pedunculated colorectal adenomas (MATILDA-trial): rationale and design of a multicenter randomized clinical trial. *BMC Gastroenterol.* 2016, **16(1)**: 56.
75. DASARI A, SHEN C, HALPERIN D, ZHAO B, ZHOU S, XU Y, *et al.* Trends in the Incidence, Prevalence, and Survival Outcomes in Patients With Neuroendocrine Tumors in the United States. *JAMA Oncol.* 2017, **3(10)**: 1335-42.
76. WASHINGTON MK, GOLDBERG RM, CHANG GJ, LIMBURG P, LAM AK, SALTO-TELLEZ M, *et al.* Diagnosis of digestive system tumours. *Int J Cancer*. 2021, **148(5)**: 1040-50.
77. DHALIWAL A, KOLLI S, DHINDSA BS, DEVANI K, RAMAI D, SAYLES H, *et al.* Clinical efficacy and safety of mucosal incision-assisted biopsy for the diagnosis of upper gastrointestinal subepithelial tumors: A systematic review and meta-analysis. *Ann Gastroenterol.* 2020, **33(2)**: 155-61.
78. DEPREZ PH, MOONS LMG, O'TOOLE D, GINCUL R, SEICEAN A, PIMENTEL-NUNES P, *et al.* Endoscopic management of subepithelial lesions including neuroendocrine neoplasms: European Society of Gastro-intestinal Endoscopy (ESGE) Guideline. *Endoscopy*. 2022, **54(4)**: 412-29.
79. KUIPER T, VAN OIJEN MGH, VAN VELTHUYSEN MF, VAN LELYVELD N, VAN LEERDAM ME, VLEGGAAR FD, *et al.* Endoscopically removed rectal NETs: a nationwide cohort study. *Int J Colorectal Dis.* 2021, **36(3)**: 535-41.
80. CHEN T, YAO LQ, XU MD, ZHANG YQ, CHEN WF, SHI Q, *et al.* Efficacy and Safety of Endoscopic Submucosal Dissection for Colorectal Carcinoids. *Clin Gastroenterol Hepatol.* 2016, **14(4)**: 575-81.
81. NAM SJ, KIM BC, CHANG HJ, JEON HH, KIM J, KIM SY. Risk Factors for Lymph Node Metastasis and Oncologic Outcomes in Small Rectal Neuroendocrine Tumors with Lymphovascular Invasion. *Gut Liver*. 2022, **16(2)**: 228-35.
82. NGAMRUENGPHONG S, KAMAL A, AKSHINTALA V, HAJIYEVA G, HANADA Y, CHEN YI, *et al.* Prevalence of metastasis and survival of 788 patients with T1 rectal carcinoid tumors. *Gastrointest Endosc*. 2019, **89(3)**: 602-6.
83. PARK HW, BYEON JS, PARK YS, YANG DH, YOON SM, KIM KJ, *et al.* Endoscopic submucosal dissection for treatment of rectal carcinoid tumors. *Gastrointest Endosc*. 2010, **72(1)**: 143-9.
84. ZHANG HP, WU W, YANG S, LIN J. Endoscopic treatments for rectal neuroendocrine tumors smaller than 16 mm: a meta-analysis. *Scand J Gastroenterol*. 2016, **51(11)**: 1345-53.
85. KANEKO H, HIRASAWA K, KOH R, KOBAYASHI R, KOKAWA A, TANAKA K, *et al.* Treatment outcomes of endoscopic resection for rectal carcinoid tumors: an analysis of the resectability and long-term results from 46 consecutive cases. *Scand J Gastroenterol.* 2016, **51(12)**: 1489-94.
86. INADA Y, YOSHIDA N, FUKUMOTO K, HIROSE R, INOUE K, DOHI O, *et al.* Risk of lymph node metastasis after endoscopic treatment for rectal NETs 10 mm or less. *Int J Colorectal Dis.* 2021, **36(3)**: 559-67.
87. WANG X, XIANG L, LI A, HAN Z, LI Y, WANG Y, *et al.* Endoscopic submucosal dissection for the treatment of rectal carcinoid tumors 7-16 mm in diameter. *Int J Colorectal Dis.* 2015, **30(3)**: 375-80.
88. BRAND M, REIMER S, REIBETANZ J, FLEMMING S, KORNMANN M, MEINING A. Endoscopic full thickness resection vs. transanal endoscopic microsurgery for local treatment of rectal neuroendocrine tumors - a retrospective analysis. *Int J Colorectal Dis.* 2021, **36(5)**: 971-6.
89. PARK SS, KIM BC, LEE DE, HAN KS, KIM B, HONG CW, *et al.* Comparison of endoscopic submucosal dissection and transanal endoscopic microsurgery for T1 rectal neuroendocrine tumors: a propensity score-matched study. *Gastrointest Endosc*. 2021, **94(2)**: 408-15.e2.
90. CHOI YS, LEE JB, LEE EJ, LEE SH, SUH JP, LEE DH, *et al.* Can endoscopic submucosal dissection technique be an alternative treatment option for a difficult giant (≥ 30 mm) pedunculated colorectal polyp? *Dis Colon Rectum.* 2013, **56(5)**: 660-6.
91. CHIBA H, TACHIKAWA J, ARIMOTO J, ASHIKARI K, KUWABARA H, NAKAOKA M, *et al.* Endoscopic submucosal dissection of large pedunculated polyps with wide stalks: a retrospective multicenter study. *Endoscopy*. 2021, **53(1)**: 77-80.
92. SUZUKI T, KITAGAWA Y, NANKINZAN R, HARA T, YAMAGUCHI T. Feasibility of endoscopic submucosal dissection for recurrent colorectal tumors after endoscopic mucosal resection. *Acta Gastroenterol Belg.* 2019, **82(3)**: 375-8.
93. HURLSTONE DP, SHORTHOUSE AJ, BROWN SR, TIFFIN N, CROSS SS. Salvage endoscopic submucosal dissection for residual or local recurrent intraepithelial neoplasia in the colorectum: a prospective analysis. *Colorectal Dis*. 2008, **10(9)**: 891-7.
94. RAHMI G, TANAKA S, OHARA Y, ISHIDA T, YOSHIZAKI T, MORITA Y, *et al.* Efficacy of endoscopic submucosal dissection for residual or recurrent superficial colorectal tumors after endoscopic mucosal resection. *J Dig Dis.* 2015, **16(1)**: 14-21.
95. SAKAMOTO T, SAITO Y, MATSUDA T, FUKUNAGA S, NAKAJIMA T, FUJII T. Treatment strategy for recurrent or residual colorectal tumors after endoscopic resection. *Surg Endosc.* 2011, **25(1)**: 255-60.
96. KOBAYASHI R, HIRASAWA K, IKEDA R, DE FUKUCHI T, ISHII Y, KANEKO H, *et al.* The feasibility of colorectal endoscopic submucosal dissection for the treatment of residual or recurrent tumor localized in therapeutic scar tissue. *Endosc Int Open.* 2017, **5(12)**: E1242-e50.
97. ITO S, HOTTA K, IMAI K, YAMAGUCHI Y, KISHIDA Y, TAKIZAWA K, *et al.* Treatment strategy for local recurrences after endoscopic resection of a colorectal neoplasm. *Surg Endosc.* 2019, **33(4)**: 1140-6.
98. TANAKA H, OKA S, TANAKA S, NAGATA S, KUNIHIRO M, KUWAI T, *et al.* Salvage endoscopic submucosal dissection for local residual/recurrent colorectal tumor after endoscopic resection: Large multicenter 10-year study. *Dig Endosc.* 2021, **33(4)**: 608-15.
99. KUROKI Y, HOTEYA S, MITANI T, YAMASHITA S, KIKUCHI D, FUJIMOTO A, *et al.* Endoscopic submucosal dissection for residual/locally recurrent lesions after endoscopic therapy for colorectal tumors. 2010, **25(11)**: 1747-53.

100. FALLER J, JACQUES J, OUNG B, LEGROS R, RIVORY J, SUBTIL F, *et al.* Endoscopic submucosal dissection with double clip and rubber band traction for residual or locally recurrent colonic lesions after previous endoscopic mucosal resection. *Endoscopy*. 2020, **52(5)**: 383-8.
101. ISHIDA T, YOSHIDA N, INOUE K, DOHI O, ITOH Y. A recurrent lesion with severe fibrosis of colorectal endoscopic submucosal dissection using the combination of pocket-creation method and traction device. *VideoGIE.* 2020, **5(12)**: 686-7.
102. NOMURA T, HAYASHI Y, MORIKAWA T, OKADA M, FUKUDA H, TAKEZAWA T, *et al.* Colorectal endoscopic submucosal dissection using the pocket-creation method with single clip traction: a feasibility study. *Endosc Int Open.* 2021, **9(5)**: E653-e8.
103. ISHII H, FUKUDA H, HAYASHI Y, MORIKAWA T, TANIGUCHI O, LEFOR AK, *et al.* A traction wire facilitates the pocket-creation method for endoscopic submucosal dissection in the cecum. *Endoscopy*. 2022.
104. MORIKAWA T, FUKUDA H, HAYASHI Y. Muscular defect resembling a perforation during endoscopic submucosal dissection at the base of a residual appendix after open appendectomy. *Dig Endosc.* 2022, **34(3)**: e44-e5.
105. JUNG WB, YU CS, LIM SB, PARK IJ, YOON YS, KIM JC. Anastomotic Recurrence After Curative Resection for Colorectal Cancer. *World J Surg.* 2017, **41(1)**: 285-94.
106. HORII J, URAOKA T, GOTO O, ISHII H, SHIMODA M, YAHAGI N. Endoscopic submucosal dissection of colorectal neoplasia located on the suture line of anastomosis. *Clin J Gastroenterol.* 2014, **7(4)**: 290-4.
107. WADA M, KATO M, HIRAI Y, URAOKA T. Salvage resection of recurrent polyp after polypectomy on the colorectal anastomosis using endoscopic submucosal dissection. *Gastrointest Endosc*. 2017, **85(6)**: 1305-6.
108. MAEHATA T, KATO M, OCHIAI Y, MIZUTANI M, TSUTSUMI K, KIGUCHI Y, *et al.* Feasibility of endoscopic submucosal dissection for colorectal neoplasia at anastomotic sites: a retrospective study. *Surg Endosc*. 2020, **34(12)**: 5495-500.
109. CHEN Z, DOU L, ZHANG Y, HE S, LIU Y, LEI H, *et al.* Safety and efficacy of endoscopic submucosal dissection for metachronous early cancer or precancerous lesions emerging at the anastomotic site after curative surgical resection of colorectal cancer. *Ann Transl Med.* 2020, **8(21)**: 1411.
110. NEMOTO D, TAKEZAWA T, HAYASHI Y. ESD using the pocket-creation method enables complete resection of lesions at an anastomotic site. *Dig Endosc.* 2020, **32(6)**: e128-e9.
111. JESS T, RUNGOE C, PEYRIN-BIROULET L. Risk of colorectal cancer in patients with ulcerative colitis: a meta-analysis of population-based cohort studies. *Clin Gastroenterol Hepatol.* 2012, **10(6)**: 639-45.
112. LAINE L, KALTENBACH T, BARKUN A, MCQUAID KR, SUBRAMANIAN V, SOETIKNO R. SCENIC international consensus statement on surveillance and management of dysplasia in inflammatory bowel disease. *Gastrointest Endosc*. 2015, **81(3)**: 489-501.e26.
113. PARRA-BLANCO A, RAGUNATH K. Endoscopic submucosal dissection for inflammatory bowel disease-related dysplasia: feasible, but be ready for a difficult procedure. *Endoscopy*. 2017, **49(12)**: 1200-1.
114. IACOPINI F, SAITO Y, YAMADA M, GROSSI C, RIGATO P, COSTAMAGNA G, *et al.* Curative endoscopic submucosal dissection of large nonpolypoid superficial neoplasms in ulcerative colitis (with videos). *Gastrointest Endosc*. 2015, **82(4)**: 734-8.
115. SUZUKI N, TOYONAGA T, EAST JE. Endoscopic submucosal dissection of colitis-related dysplasia. *Endoscopy*. 2017, **49(12)**: 1237-42.
116. SMITH LA, BARAZA W, TIFFIN N, CROSS SS, HURLSTONE DP. Endoscopic resection of adenoma-like mass in chronic ulcerative colitis using a combined endoscopic mucosal resection and cap assisted sub-mucosal dissection technique. *Inflamm Bowel Dis*. 2008, **14(10)**: 1380-6.
117. KINOSHITA S, NISHIZAWA T, YAHAGI N, URAOKA T. Endoscopic Submucosal Dissection in Patients with Ulcerative Colitis. *Digestion*. 2019, **99(1)**: 27-32.
118. YANG DH, REY I. Endoscopic Submucosal Dissection for Colitis-Associated Dysplasia. *Clin Endosc.* 2019, **52(2)**: 120-8.
119. KASUGA K, YAMADA M, SHIDA D, TAGAWA T, TAKAMARU H, SEKIGUCHI M, *et al.* Treatment outcomes of endoscopic submucosal dissection and surgery for colorectal neoplasms in patients with ulcerative colitis. *United European Gastroenterol J*. 2021, **9(8)**: 964-72.
120. MANTA R, ZULLO A, TELESCA DA, CASTELLANI D, GERMANI U, REGGIANI BONETTI L, *et al.* Endoscopic Submucosal Dissection for Visible Dysplasia Treatment in Ulcerative Colitis Patients: Cases Series and Systematic Review of Literature. *J Crohns Colitis.* 2021, **15(1)**: 165-8.
121. MATSUI A, HOTEYA S, HAYASAKA J, YAMASHITA S, OCHIAI Y, SUZUKI Y, *et al.* Real-World Experience of Endoscopic Submucosal Dissection for Ulcerative Colitis-Associated Neoplasia. *Inflamm Intest Dis*. 2021, **6(2)**: 70-7.
122. MATSUMOTO K, OKA S, TANAKA S, TANAKA H, BODA K, YAMASHITA K, *et al.* Long-Term Outcomes after Endoscopic Submucosal Dissection for Ulcerative Colitis-Associated Dysplasia. *Digestion*. 2021, **102(2)**: 205-15.